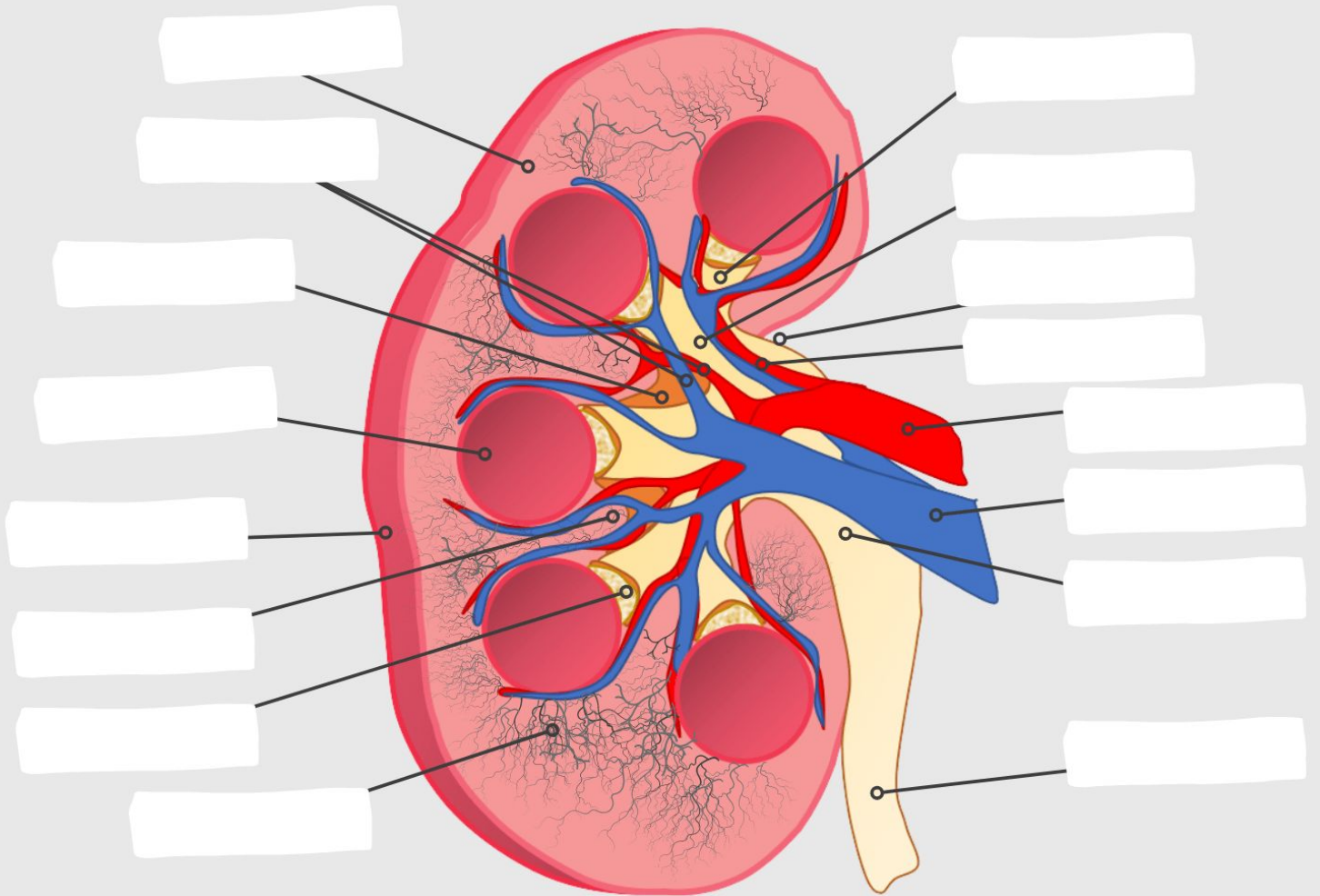


Anatomy of a Kidney



WORD BANK

Renal pyramid Medullary rays Renal column Ureter Renal artery Renal vein Cortex Medulla (pyramid) Renal capsule
Renal sinus space Hilum Renal pelvis Renal sinus arteries & veins
Renal papilla Segmental artery Major calyx Minor calyx