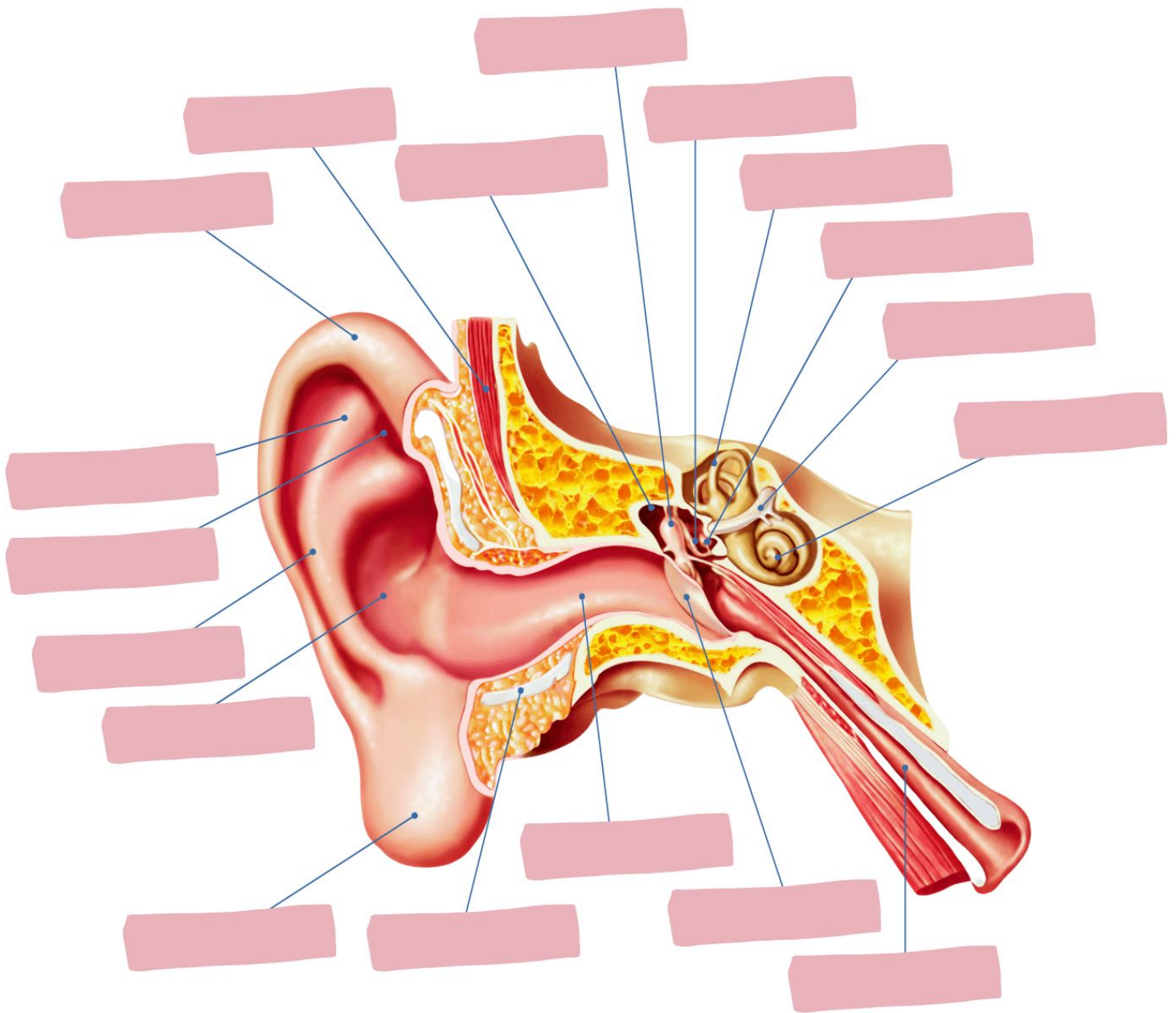


Name:

Date:

ANATOMY OF THE EAR



Word Bank:

Concha Antihelix Vestibular Nerve Incus Stapes Malleus Scapha Helix
Triangular Fossa Auricular Lobule Cartilage Temporal Muscle Temporal Bone
External Acoustic Meatus Tympanic Membrane Eustachian Tube Cochlea
Semicircular Canals Tympanic Cavity