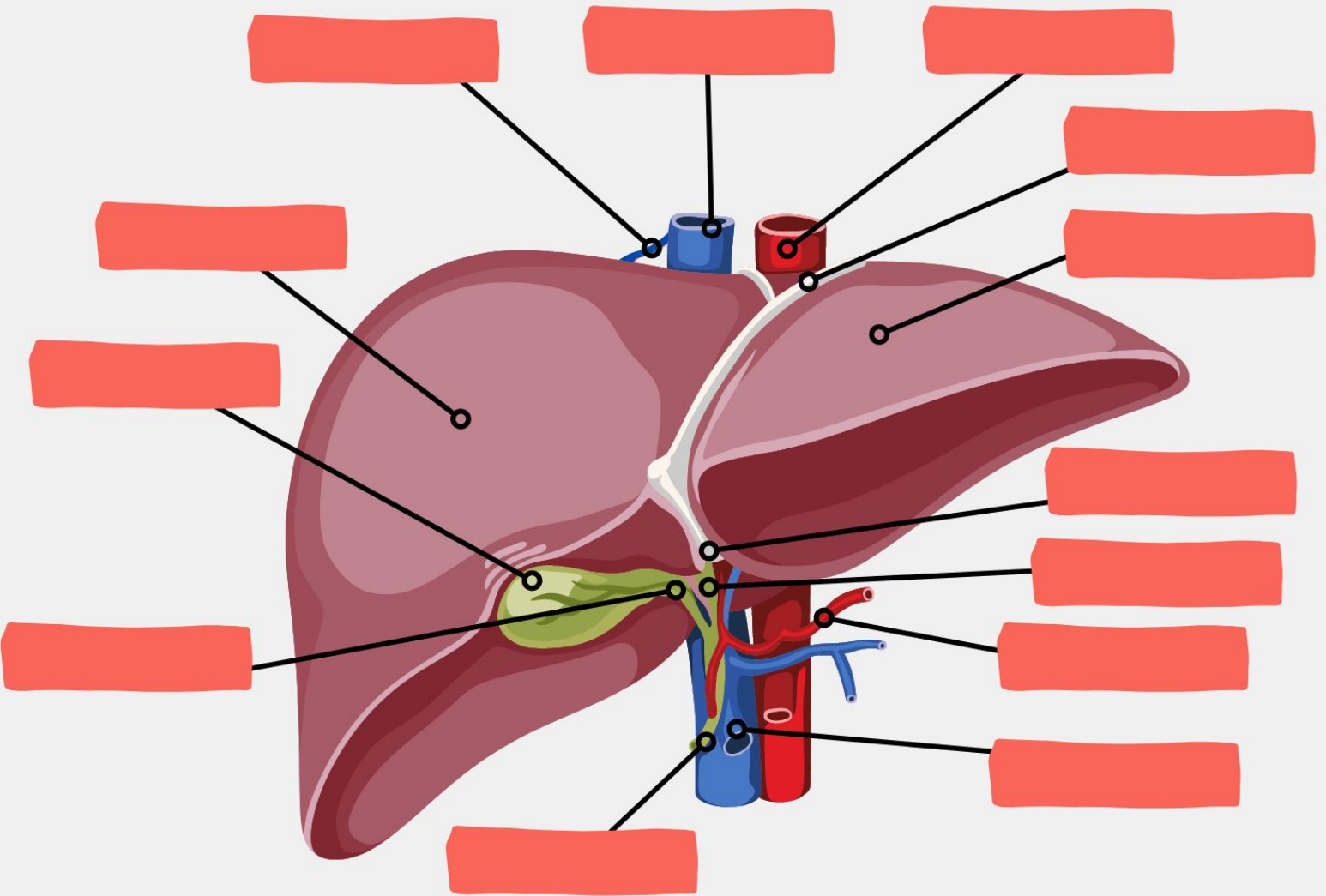


Name:

Date:

Anatomy of the Liver



Wordbank

Hepatic vein Cystic duct Hepatic portal vein Hepatic artery
Teres ligament Aorta Left lobe Right lobe Gallbladder
Inferior vena cava Common duct Hepatic duct Falciform ligament