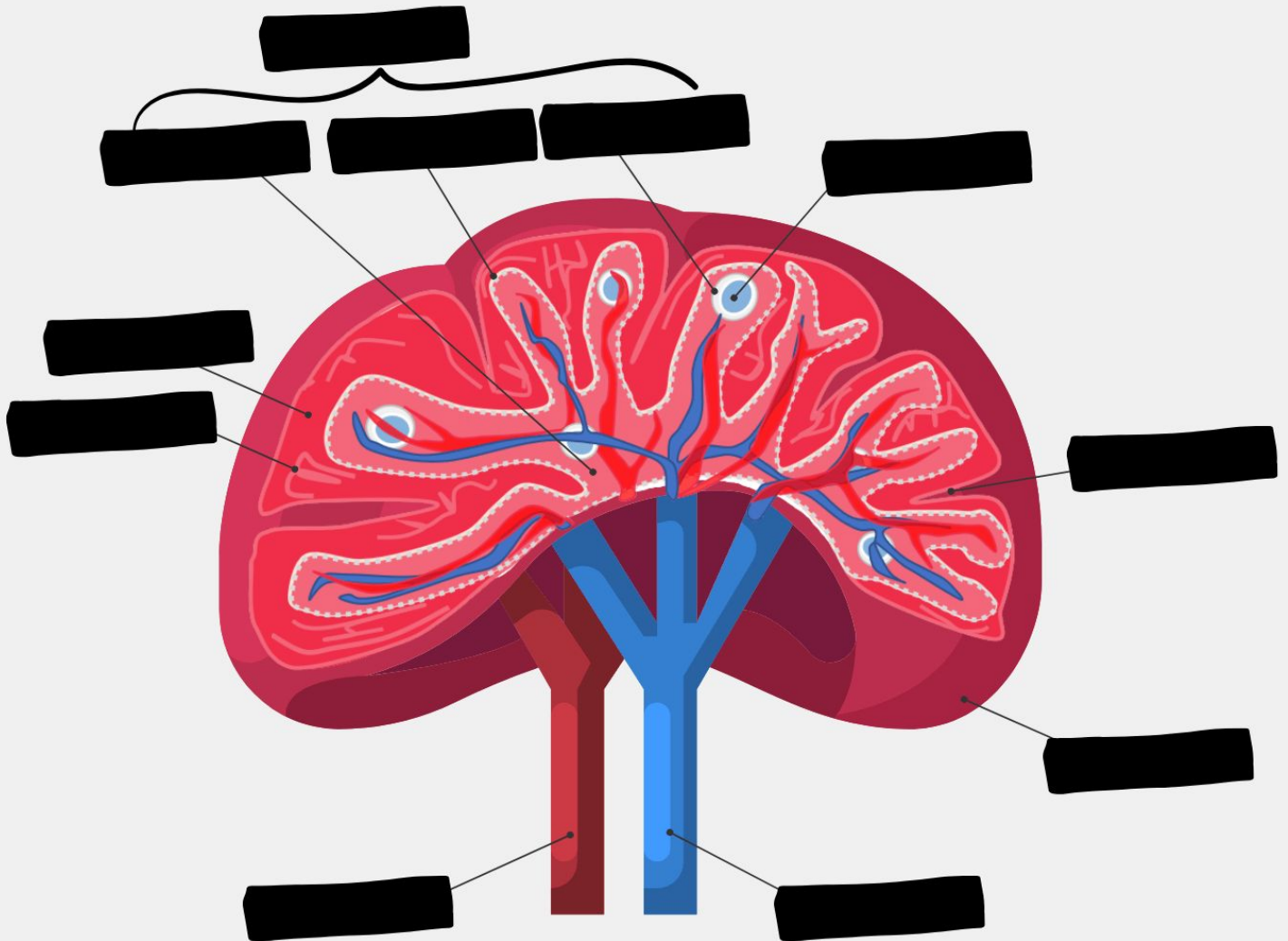


Name:

Date:

Anatomy of the Spleen



Word Bank

Artery Vein White Pulp Vascular Sinusoid Red Pulp Capsule Germinal Centre
Periarterial Lymphatic Sheath Primary Follicle Marginal Zone Trabecula