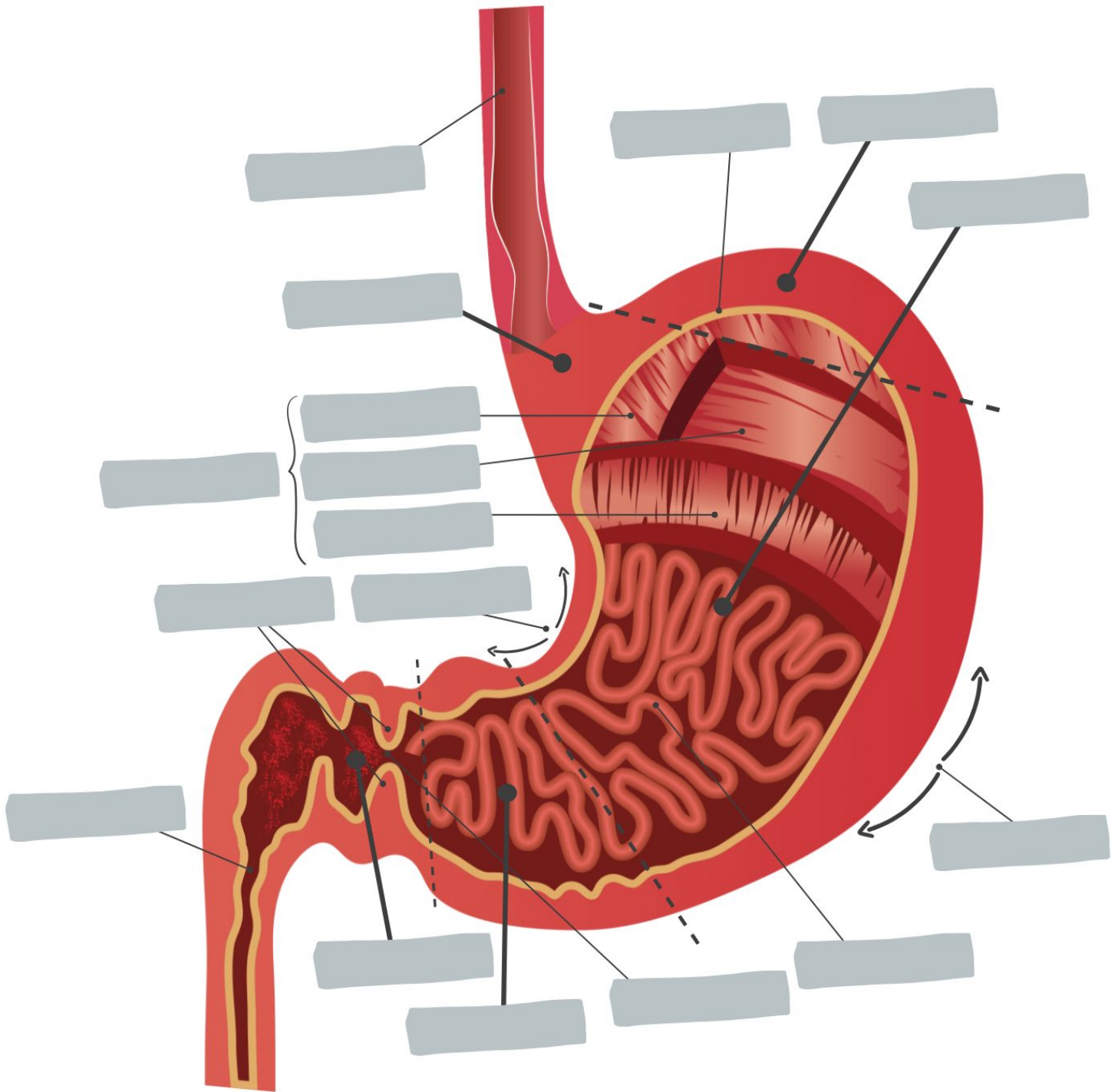


Name:

Date:

Anatomy of the Stomach



Word Bank

Pylorus Rugae of mucosa Body Serosa Cardia Duodenum Pyloric Sphincter
Lesser Curvature Greater Curvature Pyloric Canal Pyloric Atrium Oblique Layer
Longitudinal Layer Circular Layer Muscularis Externa Esophagus Fundus